



**ACCURATE TESTING
AND DIAGNOSIS OF
*GIARDIA***

vetscan IMAGYST™

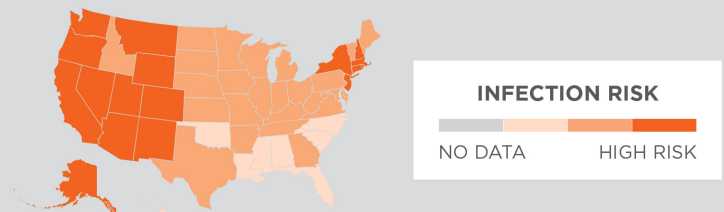
ACCURATE TESTING AND DIAGNOSIS OF *GIARDIA*

Yoko Nagamori, DVM, MS, DACVM-Parasit. Veterinary Specialist—Parasitology
Cory D. Penn, DVM Global Diagnostic Medical Lead—Diagnostic Platforms

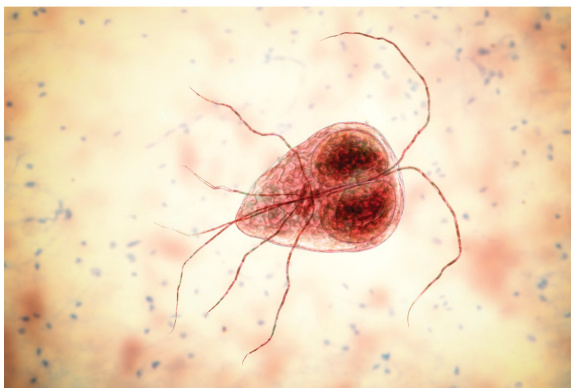
INTRODUCTION

Giardia duodenalis (syn *G. lamblia*, *G. intestinalis*) is a gastrointestinal parasite of mammals found worldwide.¹ In the United States, *G. duodenalis* infection is common in dogs and cats but can be challenging to diagnose.² The prevalence of *G. duodenalis* infection varies depending on the age, clinical status, housing and geographic region of the animal and is influenced by the detection method employed.^{3,4}

2021 CAPC *GIARDIA* PREVALENCE MAP⁷



3D ILLUSTRATION OF TROPHOZOITE



Giardia exists in 2 stages:

TROPHOZOITE Motile stage in small intestine

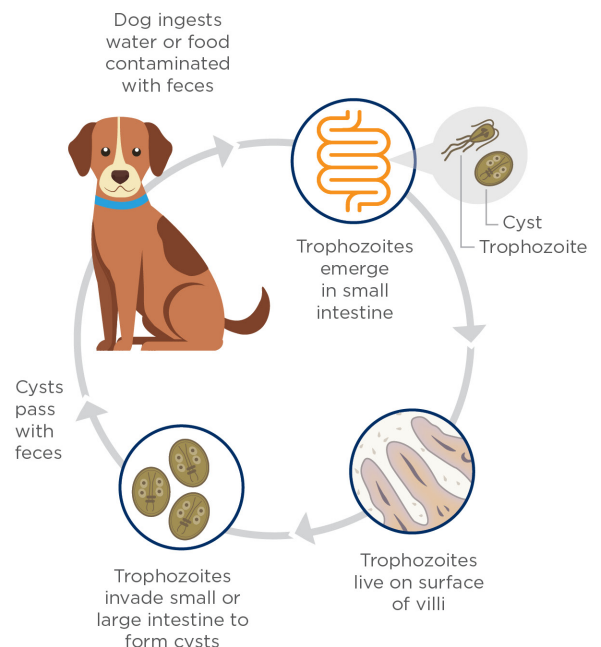
Trophozoites are usually 12 to 17 μm by 7 to 10 μm in size.⁵ They are motile, flagellated organisms that originate from cysts and appear teardrop or pear-shaped.⁶ Trophozoites are bilaterally symmetrical and have two nuclei, each with a large endosome. They also have a pair of transverse, dark-staining median bodies. Trophozoites inhabit the mucosal surfaces of the small intestine where they attach to the brush border, absorb nutrients and multiply by binary fission. They usually live in the proximal portion of the small intestine.²

CYST Infective stage responsible for environmental contamination

Trophozoites invade the small or large intestine to form cysts. Cysts are ellipsoidal, nonmotile and contain 2 to 4 nuclei with long- and short-curved rods. They are 9 to 13 μm by 7 to 9 μm in size and possess a thick refractile wall. Newly formed cysts pass in the feces. Cyst shedding may be continual over several days and weeks but is often intermittent, especially in the chronic phase of infection. Cysts can survive for several weeks to months in the environment, whereas trophozoites cannot.^{5,7}

Upon infection, dogs and cats may be asymptomatic or present with symptoms such as weight loss and diarrhea, which can be continual or intermittent, particularly in puppies and kittens. When symptomatic, feces are usually soft, poorly formed, pale, malodorous, contain mucus and appear fatty. Watery diarrhea is unusual in uncomplicated cases, and blood is usually not present in feces. Occasionally, vomiting occurs. Minimum database clinical laboratory findings are usually normal.³

LIFE CYCLE OF *GIARDIA*





TESTING FOR *GIARDIA* PRESENTS CHALLENGES

It is very challenging to correctly diagnose a *Giardia* infection, and in fact, *Giardia* is one of the most commonly over and underdiagnosed parasites. It can easily be mistaken for many other objects (pseudoparasites) within the feces, such as yeast, that can lead to potential overdiagnosis. *Giardia* can also be underdiagnosed, as cysts may be shed intermittently and can deteriorate in fecal solutions very quickly, making detection and identification more difficult. Given these complexities, there is no easy, quick test with 100% accuracy when it comes to diagnosing a *Giardia* infection, but there are many tests that can be used in conjunction to detect its presence.^{2,3,7}

WHEN IS TESTING FOR *GIARDIA* APPROPRIATE?

According to the Companion Animal Parasite Council (CAPC), veterinarians should screen cats or dogs for *Giardia* when they show symptoms such as chronic or intermittent diarrhea.⁷

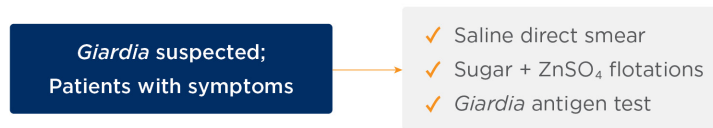
Additionally, patients at higher risk for *Giardia* infection, such as young animals or those at higher risk of contracting giardiasis due to lifestyle, may benefit from *Giardia* screening at routine wellness examinations.^{1,2}

HOW TO TEST FOR *GIARDIA*

GIARDIA DIAGNOSIS

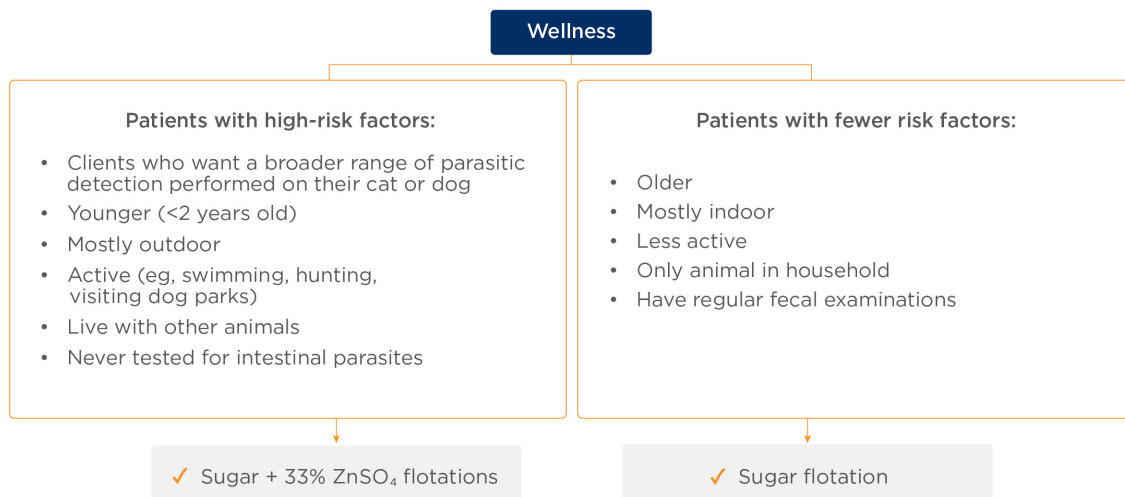
CAPC recommends testing symptomatic animals for *Giardia* with a combination of direct smear (detection of trophozoites), fecal flotation with centrifugation (detection of cysts), and fecal antigen test optimized for use in companion animals to detect *Giardia* antigen.⁷ Multiple tests performed over several (usually alternating) days may be necessary to identify infection because of the possibility of intermittent shedding of cysts.²

TESTING ALGORITHM



Testing for a broader range of parasites by fecal flotation with centrifugation using both 33% Zinc Sulfate solution and sugar solutions may also be warranted at wellness visits in patients who are asymptomatic but have high-risk factors for giardiasis. In asymptomatic patients with fewer risk factors, fecal flotation with centrifugation using only a sugar solution is recommended.^{5,7}

SOLUTION ALGORITHM



The 3 tests CAPC recommends to aid in the diagnosis of a *Giardia* infection differ in several ways, including methodology, what is being detected (cyst vs trophozoite), and level of expertise and resources needed to conduct the test.⁷

DIRECT SMEAR

Direct smear is used primarily for detection of trophozoites in diarrheic stools. CAPC recommends using a small sample of fresh, unrefrigerated feces (preferably less than 30 minutes old). The sample should be mixed into 2 to 3 drops of saline (not water) on a glass slide to make a fine suspension. Then a coverslip is added, and the sample is viewed under a microscope. A Lugol iodine stain may be added to aid in identification.^{4,5}

ANTIGEN TESTING

Giardia antigen testing can be a helpful test to use in conjunction with fecal flotation.⁸ Diagnosis of *Giardia* infection by visual microscopy can be very difficult, especially when there are only a few *Giardia* cysts/trophozoites on a slide, and that can lead to a false-negative result.⁹ The VETSCAN® *Giardia* Rapid Test is a test that has been validated to detect *Giardia* antigen in the feces.¹⁰



FECAL FLOTATION WITH CENTRIFUGATION

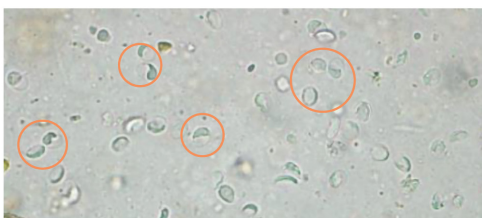
Fecal flotation with centrifugation is used primarily for detection of cysts in solid or semisolid stools.⁷ Fecal flotation requires the utilization of flotation solutions to concentrate and separate intestinal parasite eggs and cysts from fecal debris. When choosing which solution to use, one should consider the specific gravity of the solution, the viscosity of the solution and the rate of water loss of the parasite egg or cysts caused by the hypertonicity of the solution.

Many solutions can distort or damage *Giardia* cysts, further complicating cyst identification.⁵ A 33% ZnSO₄ solution is the preferred solution for *Giardia* cyst identification but is less effective for flotation testing of other common intestinal parasite eggs.⁶

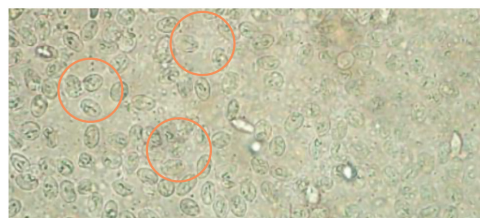
ADVANTAGES AND DISADVANTAGES OF DIFFERENT SOLUTIONS⁵

FLOTATION SOLUTION	SPECIFIC GRAVITY	ADVANTAGES	DISADVANTAGES
33% Zinc sulfate (ZnSO ₄)	1.18	Floats common helminth and protozoa eggs and cysts; preferred for <i>Giardia</i>	Less effective for flotation of common tapeworm eggs than others; does not float some fluke and some unusual tapeworm and nematode eggs
Sheather's sugar solution	1.25	Floats common helminth and protozoa eggs and cysts; causes less damage to parasite eggs and cysts than salt solutions	Less sensitive than 33% ZnSO ₄ for <i>Giardia</i> ; creates sticky surfaces

THE IMPORTANCE OF 33% ZnSO₄ SOLUTION ON *GIARDIA* SAMPLES Improved *Giardia* detection with sugar vs ZnSO₄



Giardia cysts in sugar solution



Giardia cysts in 33% ZnSO₄ solution


Images courtesy of Dr. Yoko Nagamori.

FECAL FLOTATION USING **vetscan** IMAGYST™

Even when best practices for fecal testing are followed, *Giardia* cysts may still be difficult to correctly identify, especially for less experienced or suboptimally trained staff. The VETSCAN IMAGYST™ was developed to provide a simple, easy and structured fecal examination that is less influenced by different fecal preparation methods or level of experience of an examiner. The VETSCAN IMAGYST utilizes an automated scanner and a cloud-based, deep-learning algorithm to locate, classify and identify parasite eggs and cysts found on fecal microscope slides to help overcome the challenges in manual scanning and identification.¹¹

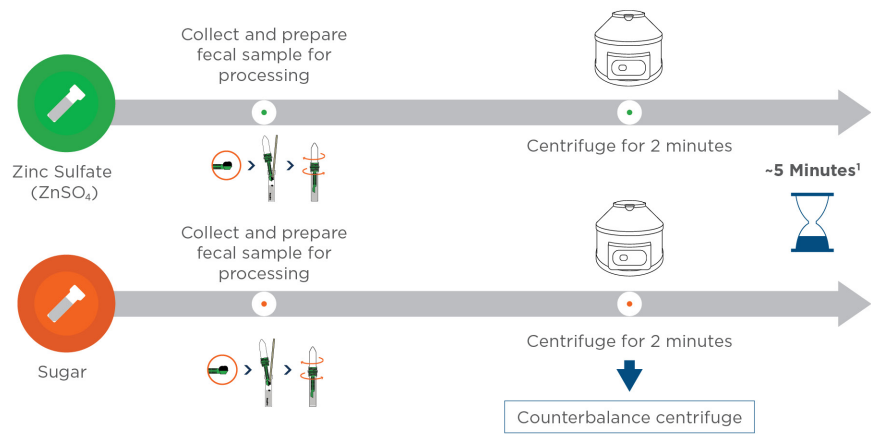
The VETSCAN IMAGYST system consists of 3 components: sample preparation, scanning of the sample by whole slide imaging (WSI) and analysis performed by a cloud-based, deep-learning algorithm. The VETSCAN IMAGYST sample preparation device is used for a centrifugal flotation technique with a transfer loop for easy transfer of the sample to a microscope slide. The VETSCAN IMAGYST applies a deep-learning, object-detection algorithm that automatically learns the most differentiating features of interest, allowing the algorithm to perceive and distinguish the morphology of parasite eggs and cysts from other objects on fecal flotation slides.¹¹

In a performance study, the VETSCAN IMAGYST sample preparation method was shown to be comparable to the performance of conventional centrifugal flotation for *Giardia* as read by an expert (clinical parasitologist) with manual microscopy. The VETSCAN IMAGYST algorithm showed good performance (sensitivity and specificity) across the different parasites tested when compared to the clinical parasitologist. In addition, using the VETSCAN IMAGYST, the availability of both sugar and 33% ZnSO₄ solutions can provide a more complete fecal diagnostic evaluation.⁸

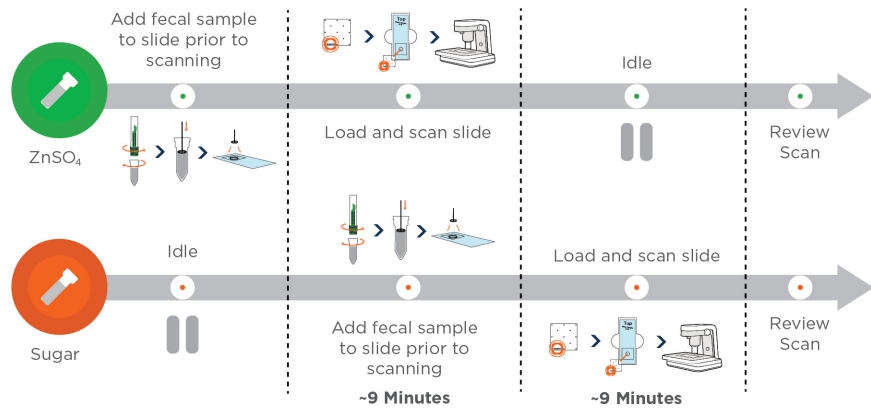


TESTING FOR *GIARDIA* WITH THE VETSCAN IMAGYST USING 33% ZnSO₄ AND SUGAR SOLUTIONS^{8,11,12}

SAMPLE PREPARATION (Done in parallel)



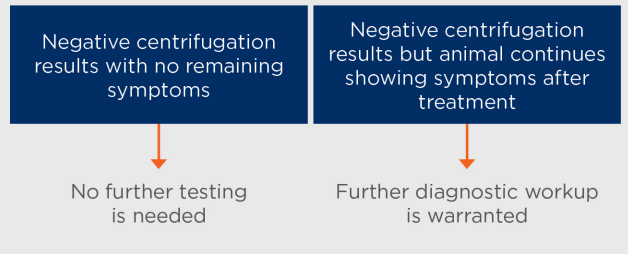
SAMPLE PROCESSING AND ANALYSIS



RETESTING MY PATIENT WHEN AND HOW?

After a giardiasis diagnosis and treatment initiation, follow-up tests are very important, especially if symptoms have not been resolved after the conclusion of therapy. Follow-up testing may be conducted 24 to 48 hours after the completion of therapy.⁷ This can be accomplished with centrifugal fecal flotation with zinc sulfate; and if this centrifugation was negative and the animal seems to be healthy, no further testing is needed.^{2,7} It is important to remember that the antigen tests can provide a false-positive result in an animal that is no longer infected with *Giardia*, because *Giardia* antigen excretion can persist for several weeks after treatment.¹⁰

RETESTING FOR *GIARDIA*: ALGORITHM USING 33% ZnSO₄ SOLUTION^{2,7}:



CONCLUSION

Testing for *Giardia* is complicated and requires the use of several types of diagnostic tools. In addition to best practices described in this paper, there are innovative platforms that can also be used to aid in the identification of *Giardia* cysts, such as the VETSCAN IMAGYST.

References: 1. Uiterwijk M, Nijsee R, Kooyma F. Host factors associated with *Giardia duodenalis* infections in dogs across multiple diagnostic tests. *Parasit Vectors*. 2019;12(1):556:1-2. doi:10.1186/s13071-019-3810-3. 2. Greene CE. Enteric protozoal infections. *Infectious Diseases of the Dog and Cat*. 4th ed. Elsevier; 2012:787. 3. Carlin EP, Bowman DD, Scarlett JM, et al. Prevalence of *Giardia* in symptomatic dogs and cats throughout the United States as determined by the IDEXX SNAP *Giardia* test. *Vet Ther*. 2006;7(3):199-206. 4. Saleh MN, Heptinstall JR, Johnson EM, et al. Comparison of diagnostic techniques for detection of *Giardia duodenalis* in dogs and cats. *J Vet Intern Med*. 2019;33(3):1272-1277. doi:10.1111/jvim.15491. 5. Zajac AM, Conboy GA, Greiner EC, et al. Fecal examination for the diagnosis of parasitism. In: Zajac AM, Conboy GA, eds. *Veterinary Clinical Parasitology*. 8th ed. Wiley-Blackwell; 2012:4-7. 6. Sahatchai T, Scorza V. Update on the diagnosis and management of *Giardia* spp infections in dogs and cats. *Top Companion Anim Med*. 2010;25(3):155-162. doi:10.1053/j.tcam.2010.07.003. 7. Companion Animal Parasite Council (CAPC) Guidelines: *Giardia*. Dog: Updated May 2019. Cat: Updated March 2018. Accessed October 22, 2019. <https://capcvet.org/guidelines/giardia>. 8. Nagamori Y, Sedlak RH, DeRosa A, et al. Further evaluation and validation of the VETSCAN IMAGYST: in-clinic feline and canine fecal parasite detection system integrated with a deep learning algorithm. *Parasit Vectors*. 2021;14(1):89. doi:10.1186/s13071-021-04591-y. 9. Dryden MW, Payne PA, Smith V. Accurate diagnosis of *Giardia* spp and proper fecal examination procedures. *Vet Ther*. 2006;7(1):4-14. PMID: 16598679. 10. Data on file, Study Report No. TI-04648. Zoetis, Inc. 11. Nagamori Y, Sedlak RH, DeRosa A, et al. Evaluation of the VETSCAN IMAGYST: an in-clinic canine and feline fecal parasite detection system integrated with a deep learning algorithm. *Parasit Vectors*. 2020;13(1):346. doi:10.1186/s13071-020-04215-x. 12. Data on file, Study Report No. D860R-US-19-078, 2019, Zoetis, Inc.